



Society for  
Maternal – Fetal  
Medicine

# Ultrasound & Antepartum Testing Services



## Who performs ultrasounds in your practice?

Physicians

Sonographers, with  
physician interpretation

Sonographers and  
physicians

Other

We bill an E/M service with the ultrasound \_\_\_\_\_.

Always

Never

Most of the  
time

Occasionally

I don't know



# Fetal testing by an MFM




- There have been significant advancements in technology and diagnostic tools
  - The use of these tools is the cornerstone of MFM practice
  - As tools have changed, codes have changed (and will continue to change)
- Let's review the tools, the associated codes, and their use...

# But before that...



- The parts of an ultrasound and other diagnostic tests
  - Professional component
  - Technical component
- **Professional Component (26)**
  - Supervision of test (if any)
  - Interpretation
  - Written report
- **Technical Component (TC)**
  - Technician salary/benefits (if any)
  - Equipment
  - Necessary supplies

# Reviewing specific modifier usage



- Performed at hospital or other facility:
  - Physician who performs or interprets the test bills the Professional Component (26)
  - Facility bills the Technical Component (TC)
- Performed at physician's office or physician owned facility:
  - Physician reports total service without a modifier



# Obstetrical ultrasounds



- CPT includes notes to help define services
- Language added to general guidelines
- “Use of ultrasound, without thorough evaluation of organ(s) or anatomic region, image documentation, and final, written report, is not separately reportable.”

# Obstetrical ultrasounds




- New guideline regarding written report(s) which states:

A written report (eg, handwritten or electronic) signed by the interpreting individual should be considered an integral part of a radiologic procedure or interpretation.

With regard to CPT descriptors for radiography services, “images” refer to those acquired in either an analog (ie, film) or digital (ie, electronic) manner.




# Obstetrical ultrasounds



- Therefore, ultrasound codes are **NOT** reported when:
  - Ultrasound is used as means to perform component of physical exam
  - Equipment does not produce hard copy or permanent digital image
  - Only brief summary noted in E/M service
- **Must document distinct, final written report with interpretation**

# Obstetrical ultrasounds




Action	Person(s) involved	Focus
Testing	Sonographer/ Physician	Performance of ultrasound exam
Results	Sonographer/ Physician	Compiling of findings from ultrasound exam
Interpretation	Physician	Determination of the meaning of the findings with consideration of clinical circumstances
Report	Physician	Work product of the interpretation of test results. Permanent report (written or digital) of results and interpretation required.

# Obstetrical ultrasounds



- An ultrasound report should include:
  - Exam performed (using CPT codes)
  - Indication for procedure (using ICD codes)
  - Interpretation of the exam/findings
  - Description of required elements or reason not visualized
  - Physician signature on interpretation and final reports

# Obstetrical ultrasounds



- If multiple services are performed:
  - Each service should be documented separately
  - The time of day for each service if performed at different times on the same day
- Communication of results to the patient is part of the service
  - We'll clarify how and where to draw the line.

# What's included?



- Post-service work
  - Preparing a complete report for the medical record
  - Reviewing and signing the prepared report
  - Discussing the **normal** findings with the patient and referring physician when appropriate



# What's not included?



- Counseling or any further discussion with the patient if there are abnormal findings, and developing management/treatment plan options
  - These can therefore be reported separately, and billed with the appropriate evaluation and management code (992xx).

# Ultrasound codes, by approach



.....

Transabdominal

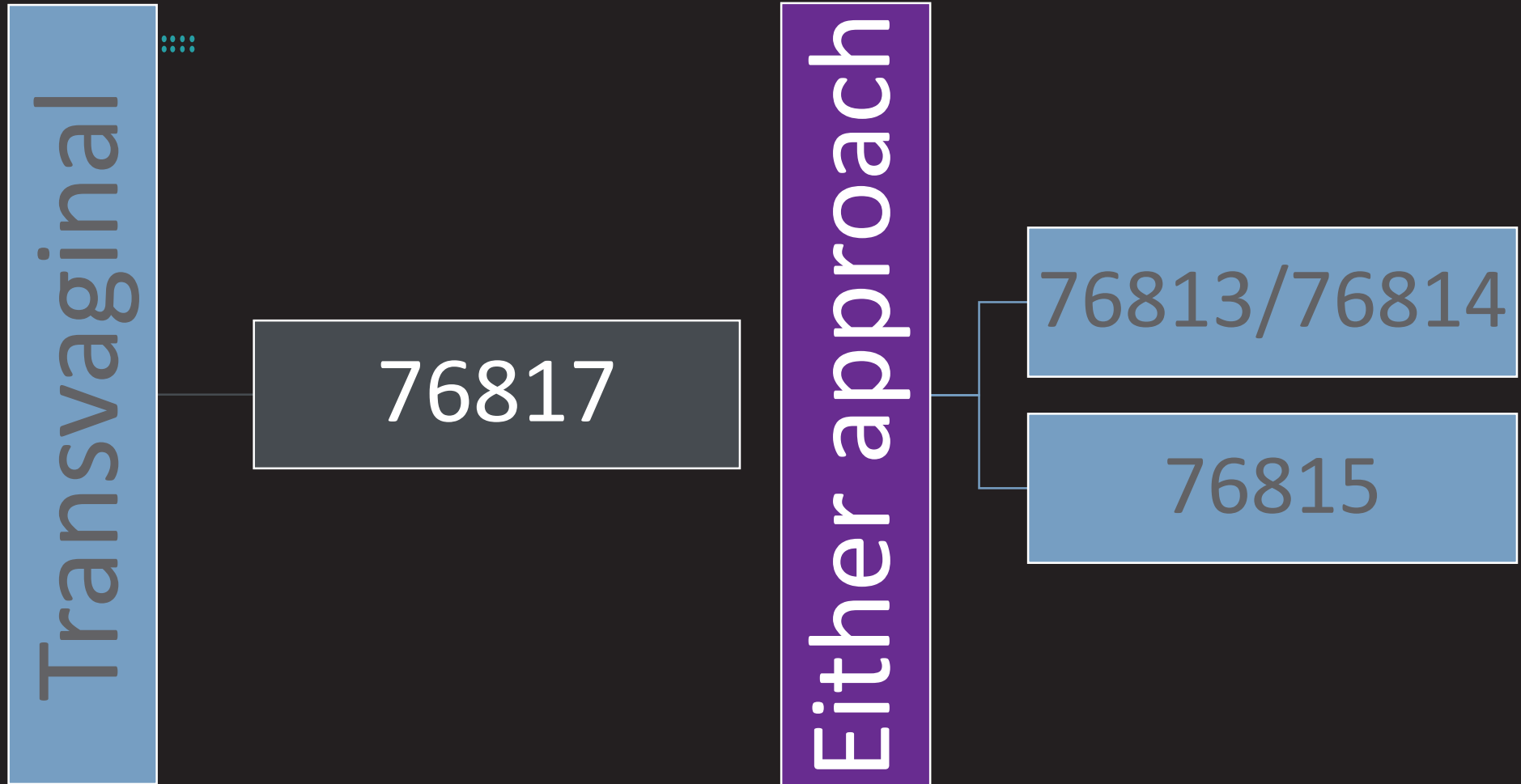
76801/76802

76805/76810

76811/76812

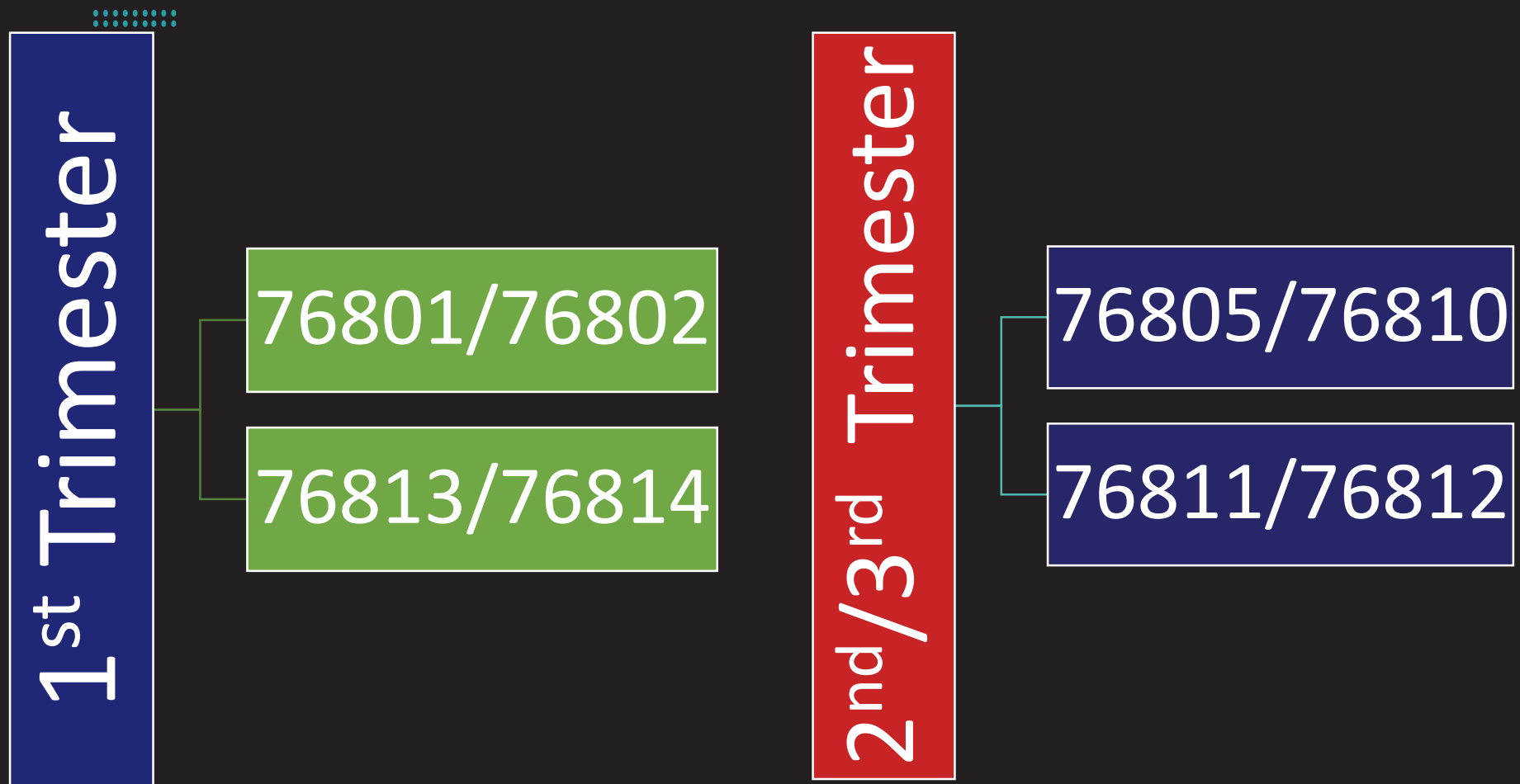
76816

# Ultrasound codes, by approach





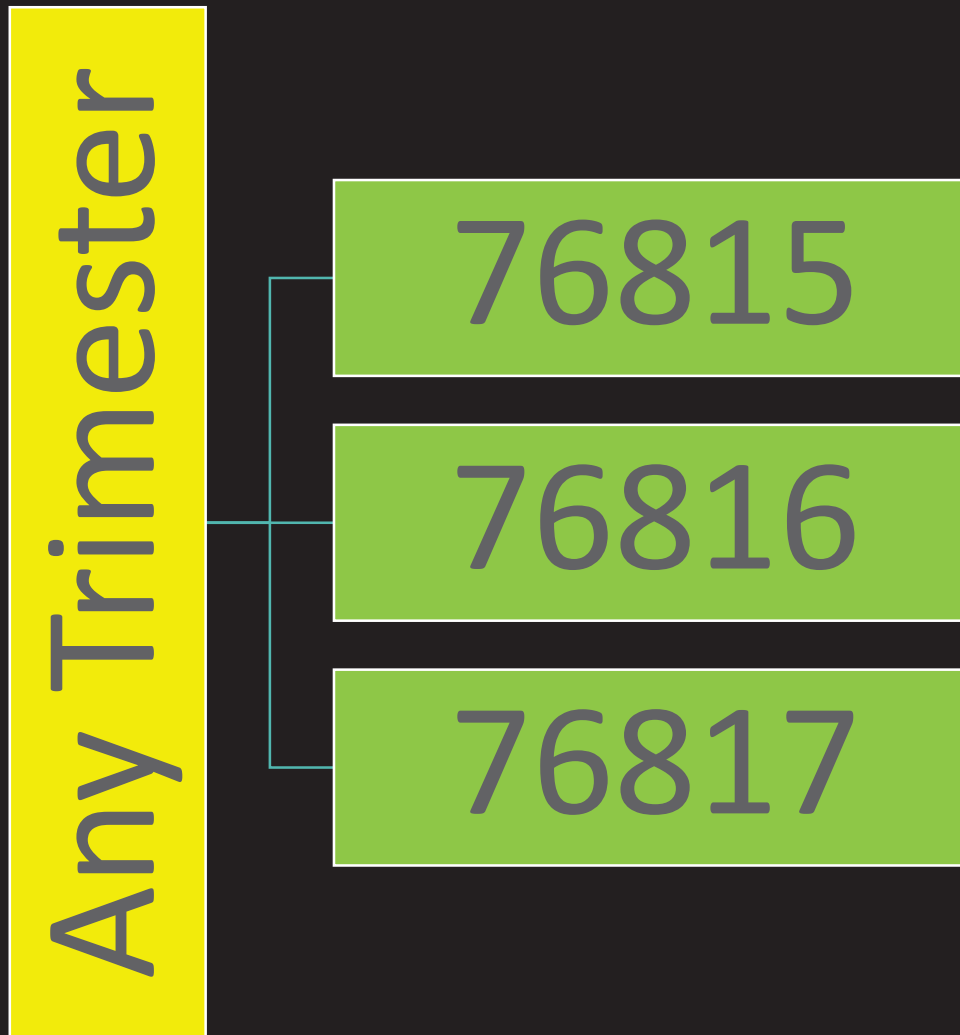
# Ultrasound codes, by trimester



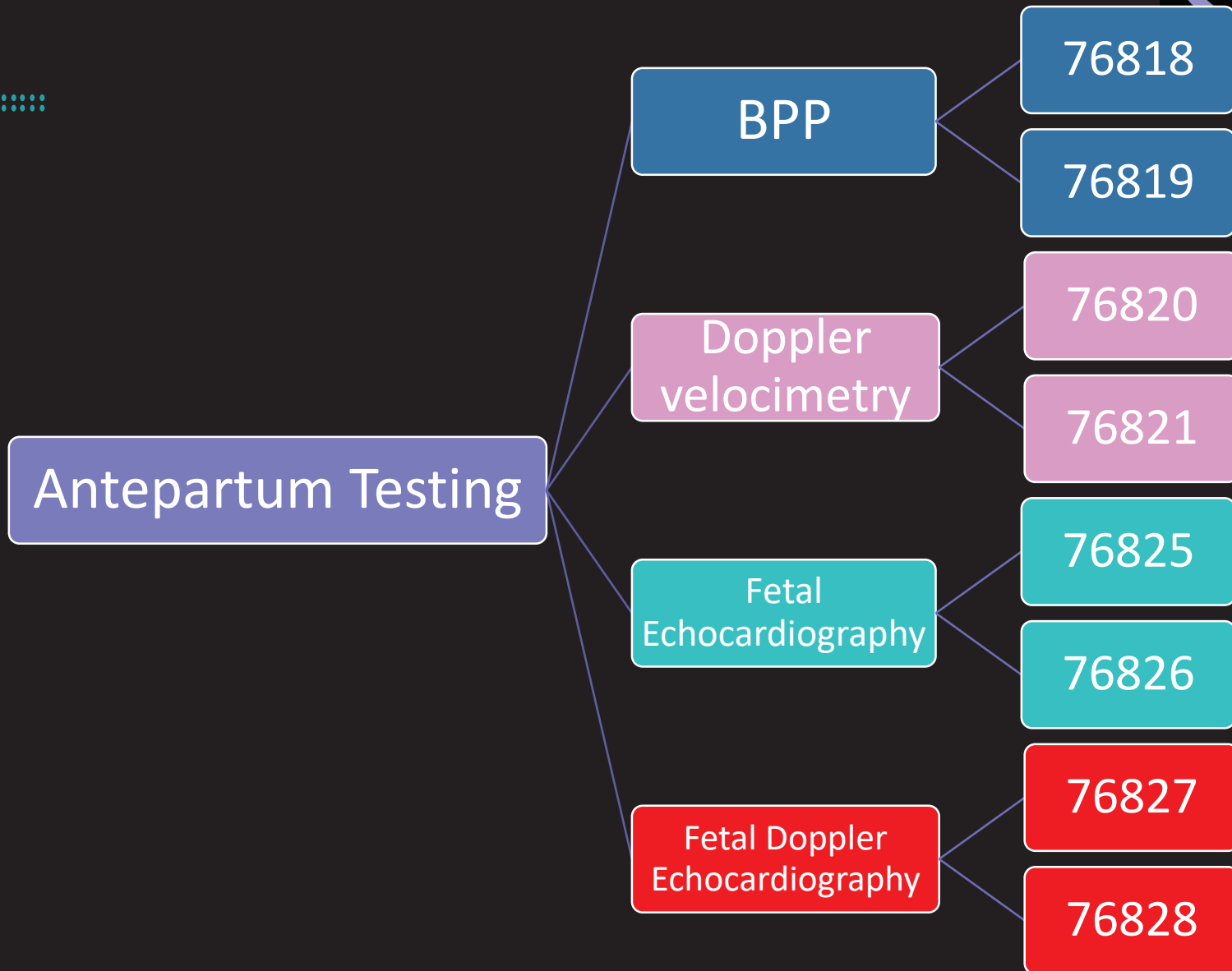
# Ultrasound codes, by trimester




.....



# Antepartum testing



# 76801/76802




**Ultrasound, pregnant uterus, real time with image documentation, fetal and maternal evaluation, first trimester (<14 weeks 0 days), transabdominal approach; single or first gestation**

**each additional gestation (List separately in addition to code for primary procedure performed)**




# 76801/76802



- Determination of the number of gestational sacs and fetuses
- Gestational sac/fetal measurements appropriate for gestation
- Survey of visible fetal and placental anatomic structure
- Qualitative assessment of amniotic fluid volume/gestational sac shape
- Examination of maternal uterus and adnexa
- Service **generally** performed for a **specific** indication (with associated diagnosis(es))

# Possible diagnoses



- Z36.87      Antenatal screening for uncertain dates
- Clinically relevant indications, such as:
  - O20.0              Threatened abortion
  - O26.891/R10.2    Oth spec preg. conditions/Pelvic pain
  - O99.-              Other maternal diseases

# Darla



- Darla is a 36 year old  $G_4P_{2012}$  who presents for an ultrasound because size was greater than dates on initial evaluation by pelvic examination. She is found to have twins on ultrasound. Dr. Dotson performs the study, which confirms the pregnancy dating, and the chorionicity of the twins. She is 12 weeks pregnant with diamniotic, monochorionic twins.

# Darla

# Dr. Dotson



21. DIAGNOSIS OR NATURE OF ILLNESS OR INJURY. Relate A-L to service line below (24E).										22. RESUBMISSION CODE		ORIG REF. NO.									
A.	<b>O26.841*</b>			B.	<b>O30.031</b>			C.	<b>O09.521</b>			D.	<b>Z3A.12</b>								
E.				F.				G.				H.				23. PRIOR AUTHORIZATION NUMBER					
I.				J.				K.				L.									
24.A. DATE(S) OF SERVICE From MM DD YY To MM DD YY						B. POS	D. PROCEDURES, SERVICES, OR SUPPLIES (Explain Unusual Circumstances) CPT MODIFIER				E. DX POINTER		F. \$ CHARGES		G. DAYS/ UNITS	I. ID QUAL	J. RENDERING PROVIDER N°				
							<b>11</b>	<b>76801</b>				<b>ABCD</b>				<b>1</b>	NPI				
							<b>11</b>	<b>76802</b>				<b>ABCD</b>				<b>1</b>	NPI				

## ICD-10 Codes

**O26.841\***

**O30.031**

**O09.521**

**Z3A.12**

## ICD-10 Description

**Uterine size-date discrepancy, 1<sup>st</sup> trimester**


**Twin pregnancy, monochorionic/diamniotic, 1<sup>st</sup> trimester**

**Supervision of elderly multigravida, 1<sup>st</sup> trimester**

**12 weeks gestation**

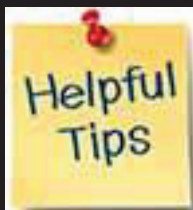

# 76813/76814



**Ultrasound, pregnant uterus, real time with image documentation, first trimester fetal nuchal translucency measurement, transabdominal or transvaginal approach; single or first gestation**

**each additional gestation (List separately in addition to code for primary procedure)**



We bill 76813 with 76801 \_\_\_\_\_.

Always

Never

When there is a  
clinical indication


I don't know

# 76813/76814

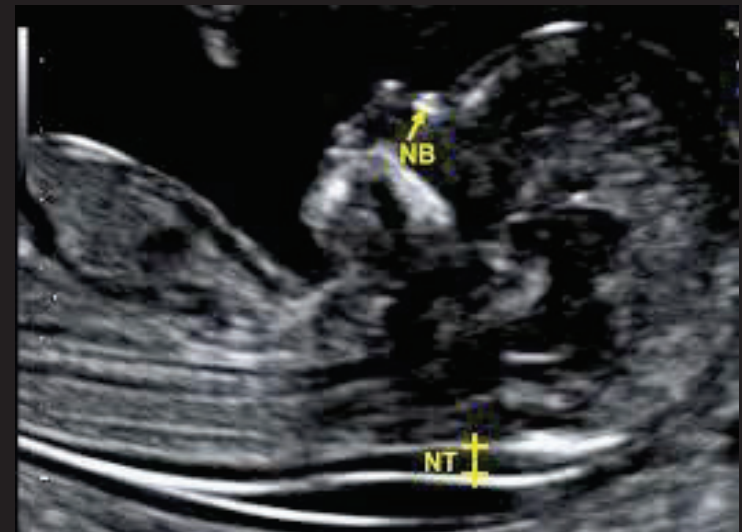


- Performed first trimester to assess risk of chromosomal abnormalities
- Transabdominal or transvaginal approach
  - Should not be billed routinely in combination with codes 76801-76802 (first trimester ultrasound)
  - Documentation should support need for both services

# 76813/76814



- These codes include three components:
  - **Fetal viability**
  - **Crown/rump measurement**
  - **Nuchal thickness measurement**
- Most likely diagnosis:
  - Z36.82 Encounter for antenatal screening for nuchal translucency



# Ellen



- Ellen is a 22 year old  $G_1P_0$  who presents for first trimester genetic screening. Her 1<sup>st</sup> trimester ultrasound at her obstetrician's office suggested a twin gestation, but this could not be confirmed with certainty. A transabdominal scan confirms that she is carrying twins. Dr. Ellerbee performs the studies, which confirms the pregnancy dating, and the chorionicity of the twins. She is 13 weeks pregnant with diamniotic, dichorionic twins.

# Ellen

# Dr. Ellerbee



21. DIAGNOSIS OR NATURE OF ILLNESS OR INJURY. Relate A-L to service line below (24E).										22. RESUBMISSION CODE			ORIG REF. NO.		
A.	<b>O30.041</b>			B.	<b>Z36.82</b>			C.	<b>Z3A.13</b>			D.			
E.				F.				G.				H.			
										23. PRIOR AUTHORIZATION NUMBER					
I.				J.				K.				L.			
24.A. DATE(S) OF SERVICE From MM DD YY To MM DD YY						B. POS	D. PROCEDURES, SERVICES, OR SUPPLIES (Explain Unusual Circumstances) CPT MODIFIER				E. DX POINTER	F. \$ CHARGES	G. DAYS/ UNITS	I. ID QUAL	J. RENDERING PROVIDER N°
							<b>11</b>	<b>76801</b>			<b>AC</b>		<b>1</b>	NPI	
							<b>11</b>	<b>76802</b>			<b>AC</b>		<b>1</b>	NPI	
							<b>11</b>	<b>76813</b>			<b>BC</b>		<b>1</b>	NPI	
							<b>11</b>	<b>76814</b>			<b>BC</b>		<b>1</b>	NPI	

## ICD-10 Codes

## ICD-10 Description

**O30.041**

**Twin pregnancy, dichorionic/diamniotic, first trimester**

**Z36.82**

**Screening for nuchal translucency**

**Z3A.13**

**13 weeks gestation of pregnancy**

## If the required measurements for a nuchal translucency can't be obtained, what can be billed?

76813

76815

76817

76813-52

Nothing can  
be billed


# The options...



- 76817 (OB Transvaginal Ultrasound)
  - Provided all required components (i.e. fetal viability) are adequately documented in the final report.
- 76815 (Limited Ultrasound Study)
- 76813-52 (Reduced Service)



76805/76810




**Ultrasound, pregnant uterus, real time with image documentation, fetal and maternal evaluation, after first trimester ( $>$  or  $=$  14 weeks 0 days), transabdominal approach; single or first gestation**

**each additional gestation (List separately in addition to code for primary procedure performed)**




# 76805/76810



- **76805/76810** includes evaluation of the following fetal and maternal components in the second and third trimesters.

The following information is based on the  
***Consensus Report on the Detailed Fetal  
Anatomic Ultrasound Examination:  
Indications, Components, and  
Qualifications***

# 76805/76810



## Head and Neck Region:

- Lateral Cerebral ventricles
- Choroid plexus
- Midline falx
- Cavum septi pellucidi
- Cerebellum
- Cisterna magna

# 76805/76810

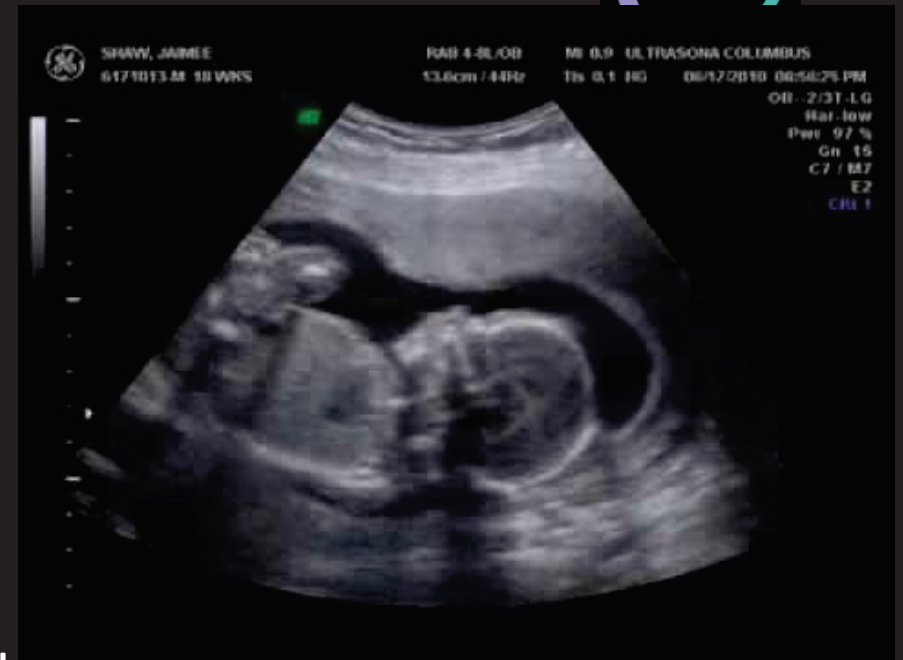.....

## Face:

- Upper Lip

## Chest:

- Cardiac activity
- Four chamber view
- Left ventricular outflow tract
- Right ventricular outflow tract




# 76805/76810



## **Abdomen:**

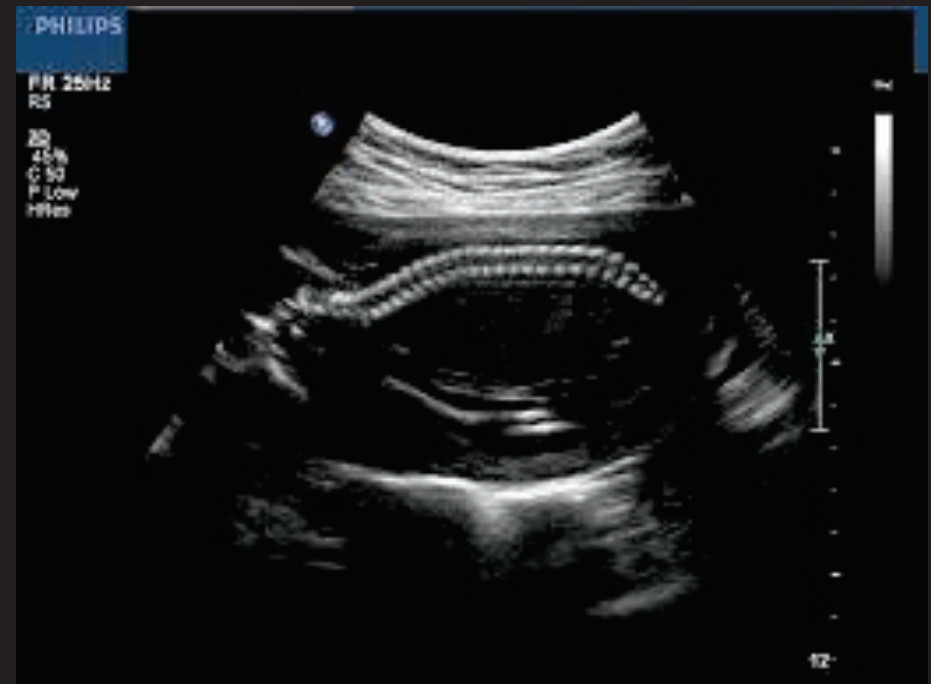- Stomach (presence, size, and situs)
- Kidneys
- Urinary Bladder
- Cord insertion site into fetal abdomen
- Umbilical cord vessel number

# 76805/76810



## Spine:

- Cervical
- Thoracic
- Lumbar
- Sacral spine



# 76805/76810




## **Extremities:**

- Legs
- Arms

## **Placenta:**

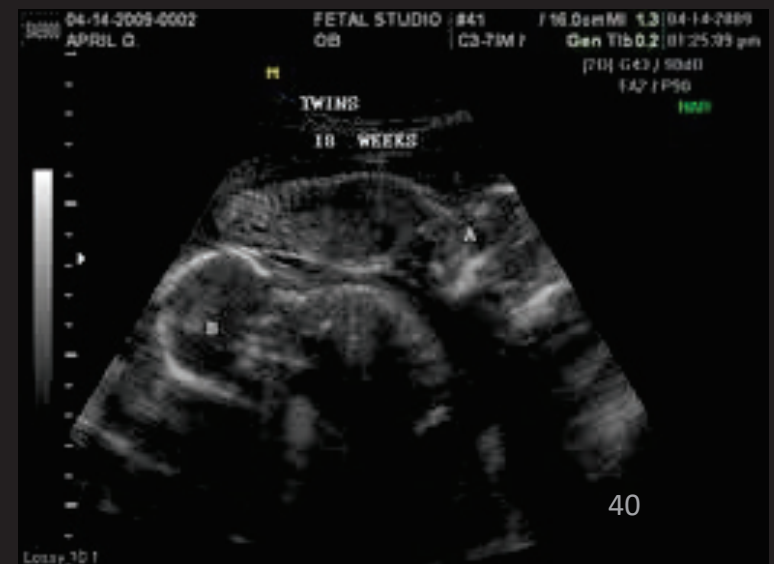- Placenta location
- Relationship to internal os
- Appearance
- Placental cord insertion (when possible)

# 76805/76810




## Standard Evaluation:

- Fetal Number
- Presentation
- Qualitative or semi-qualitative estimation of amniotic fluid





# 76805/76810



## **Biometry:**

- BPD
- Head circumference
- Femur Length
- Abdominal circumference
- Fetal weight estimate (EFW)


# 76805/76810



## Maternal Anatomy:

- Cervix (TV when indicated)
- Uterus
- Adnexa

# Possible diagnoses



- Z36.3      Antenatal screening for malformation, OR
- Clinically relevant indications, such as:
  - O09.5--      Advanced maternal age
  - O26.84-      Size/date discrepancy
  - O99.-      Other maternal diseases

# Fran



- Fran is a 26 year old  $G_2P_{1001}$  presents at 18 weeks of gestation to her obstetrician's office 120 miles away from Dr. Franklin's unit. She is known to have dichorionic twins. Her medical and family histories are unremarkable. Dr. Franklin has an agreement with that office to read their ultrasound studies remotely. The patient is unable to come to Dr. Franklin's office, so a standard twin anatomy study is done locally.

Fran

Dr. Franklin



21. DIAGNOSIS OR NATURE OF ILLNESS OR INJURY. Relate A-L to service line below (24E).										22. RESUBMISSION CODE			ORIG REF. NO.		
A.	<b>O30.042</b>			B.	<b>Z3A.18</b>			C.		D.					
E.				F.				G.		H.		23. PRIOR AUTHORIZATION NUMBER			
I.				J.				K.		L.					
24.A. DATE(S) OF SERVICE From MM DD YY To MM DD YY						B. POS	D. PROCEDURES, SERVICES, OR SUPPLIES (Explain Unusual Circumstances) CPT MODIFIER			E. DX POINTER	F. \$ CHARGES	G. DAYS/ UNITS	I. ID QUAL	J. RENDERING PROVIDER N°	
							11	76805	26	AB		1	NPI		
							11	76810	26	AB		1	NPI		

### ICD-10 Codes

O30.042

Z3A.18

### ICD-10 Description

Twin pregnancy, dichorionic/diamniotic, second trimester  
18 weeks gestation of pregnancy

76811/76812



Ultrasound, pregnant uterus, real time with image documentation, fetal and maternal evaluation **plus detailed fetal anatomic examination**, transabdominal approach; single or first gestation

each additional gestation (List separately in addition to code for primary procedure performed)




**If all elements of the detailed anatomy scan are performed,  
76811/76812 can be billed.**

True

False

I don't  
know

# 76811/76812



- It requires **everything** required in 76805/76810, **plus** the elements to be described.
- It requires an appropriate clinical indication as reflected in the *Consensus Report*.
- Some components depend on the gestational age at the time the examination is performed. Components marked with an asterisk (\*) are performed when medically indicated.



# 76811/76812



## Head and Neck Region:

- 3<sup>rd</sup> ventricle and 4<sup>th</sup> ventricle\*
- Corpus callosum\*
- Integrity and shape of cranial vault
- Brain parenchyma
- Neck

# 76811/76812



.....

## Face:

- Profile
- Coronal face (nose/lips/lens\*)
- Palate\*, maxilla, mandible and tongue\*
- Ear position and size\*
- Orbits\*

# 76811/76812



## Chest:

- Aortic arch
- SVC/IVC
- 3 vessel and trachea view
- Lungs
- Integrity of diaphragm
- Ribs\*

# 76811/76812



## **Abdomen:**

- Bowel-small and large\*
- Adrenal glands\*
- Gallbladder\*
- Liver
- Renal arteries\*
- Spleen\*

# 76811/76812



## **Spine:**

- Shape and curvature

## **Extremities:**

- Number: architecture & position
- Hands
- Feet
- Digits: number & position\*

# 76811/76812



.....

## Placenta:

- Masses
- Placental cord insertion
- Accessory/succenturiate lobe with location of connecting vascular supply to primary placenta\*

# 76811/76812



## Biometry:

- Cerebellum\*
- Inner and Outer Orbital Diameters\*
- Nuchal thickness (16-20 weeks)
- Nasal Bone measurement (15-22 weeks)
- Humerus\*
- Ulna/Radius\*
- Tibia/Fibula\*

# Grace



- Grace is a 36 year old  $G_2P_{1001}$  at 19 weeks gestation. Dr. Gibson previously evaluated her pregnancy and confirmed her dates and the chorionicity of the pregnancy. She has a diamniotic monochorionic twin gestation. Her interval history is unremarkable.



# Grace

# Dr. Gibson



21. DIAGNOSIS OR NATURE OF ILLNESS OR INJURY. Relate A-L to service line below (24E).										22. RESUBMISSION CODE			ORIG REF. NO.		
A.	<b>O30.032</b>			B.	<b>O09.522</b>			C.	<b>Z3A.19</b>			D.			
E.				F.				G.				H.			
										23. PRIOR AUTHORIZATION NUMBER					
I.				J.				K.				L.			
24.A. DATE(S) OF SERVICE From MM DD YY To MM DD YY						B. POS	D. PROCEDURES, SERVICES, OR SUPPLIES (Explain Unusual Circumstances) CPT MODIFIER				E. DX POINTER	F. \$ CHARGES	G. DAYS/ UNITS	I. ID QUAL	J. RENDERING PROVIDER N°
							<b>11</b>	<b>76811</b>				<b>ABC</b>		<b>1</b>	NPI
							<b>11</b>	<b>76812</b>				<b>ABC</b>		<b>1</b>	NPI

## ICD-10 Codes

**O30.032**

**O09.522**

**Z3A.19**


## ICD-10 Description

**Twin pregnancy, monochorionic/diamniotic, 2<sup>nd</sup> trimester**

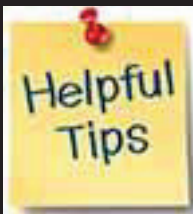**Supervision of elderly multigravida, 2<sup>nd</sup> trimester**

**19 weeks gestation**

# 76815



**Ultrasound, pregnant uterus, real time with image documentation, limited (eg, fetal heart beat, placental location, fetal position and/or qualitative amniotic fluid volume), one or more fetuses**



# 76815



.....


- The maximum number of times this service can be billed per day?
  - 1
- It is used in any trimester
- No approach designation-typically used in connection with the abdominal approach

# 76815



- “Quick look” of *one or more* of the following:
  - Fetal position
  - Fetal heart beat
  - Placental location
  - Qualitative amniotic fluid volume
- Or, a limited service when a complete service has been done elsewhere

# Helen



- Helen is a G5P3104 who is at 16 weeks 0 days, with a history of spontaneous preterm birth. She presented today for a consultation with Dr. Harlan. Dr. Harlan did a limited ultrasound to look at the placental location, which was concerning to the obstetrician on the anatomy scan earlier that week. The transabdominal scan indicated that the placenta was low-lying and posterior, but there was no previa evident.

# Helen

# Dr. Harlan



21. DIAGNOSIS OR NATURE OF ILLNESS OR INJURY. Relate A-L to service line below (24E).										22. RESUBMISSION CODE			ORIG REF. NO.			
A.	<b>O44.42</b>			B.	<b>O09.212</b>			C.	<b>Z3A.16</b>			D.				
E.				F.				G.				H.				
										23. PRIOR AUTHORIZATION NUMBER						
I.				J.				K.				L.				
24.A. DATE(S) OF SERVICE From MM DD YY To MM DD YY						B. POS	D. PROCEDURES, SERVICES, OR SUPPLIES (Explain Unusual Circumstances) CPT MODIFIER				E. DX POINTER	F. \$ CHARGES	G. DAYS/ UNITS	I. ID QUAL	J. RENDERING PROVIDER N°	
							<b>11</b>	<b>76815</b>				<b>ABC</b>		<b>1</b>	NPI	
														NPI		

## ICD-10 Codes

## ICD-10 Description

**O09.212**

Supervision of pregnancy with hx of preterm labor, 2<sup>nd</sup> trimester

**O44.42**

Low lying placenta w/o hemorrhage

**Z3A.16**

16 weeks gestation

# Helen

# Dr. Harlan



## If placenta had been normal

21. DIAGNOSIS OR NATURE OF ILLNESS OR INJURY. Relate A-L to service line below (24E).										22. RESUBMISSION CODE			ORIG REF. NO.			
A.	<b>Z03.72</b>			B.	<b>O09.212</b>			C.	<b>Z3A.16</b>			D.				
E.				F.				G.				H.				
										23. PRIOR AUTHORIZATION NUMBER						
I.				J.				K.				L.				
24.A. DATE(S) OF SERVICE From MM DD YY To MM DD YY						B. POS	D. PROCEDURES, SERVICES, OR SUPPLIES (Explain Unusual Circumstances) CPT MODIFIER				E. DX POINTER	F. \$ CHARGES	G. DAYS/ UNITS	I. ID QUAL	J. RENDERING PROVIDER N°	
							<b>11</b>	<b>76815</b>				<b>ABC</b>		<b>1</b>	NPI	
														NPI		

### ICD-10 Codes

**Z03.72**

**O09.212**

**Z3A.16**


### ICD-10 Description

**Encounter for suspected placental problem, ruled out**

**Supervision of pregnancy with hx of preterm labor, 2<sup>nd</sup> trimester**

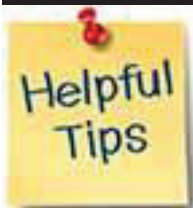**16 weeks gestation**

# 76816




.....

**Ultrasound, pregnant, uterus, real time with image documentation, *follow-up* (eg, re-evaluation of fetal size by measuring standard growth parameters and amniotic fluid volume, re-evaluation of organ system(s) suspected or confirmed to be abnormal on a previous scan), transabdominal approach per fetus**



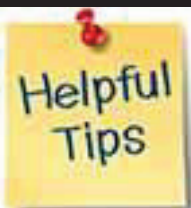

# 76816



.....

Ultrasound, pregnant, uterus, real time with image documentation, **follow-up** (eg, re-evaluation of fetal size by measuring standard growth parameters and amniotic fluid volume, re-evaluation of organ system(s) suspected or confirmed to be abnormal on a previous scan), transabdominal approach **per fetus**



# 76816



.....

- “Follow up” strongly implies a previous ultrasound
  - CPT says...
    - “designed to **reassess** fetal size and interval growth or **reevaluate** one or more anatomic abnormalities of a fetus **previously demonstrated** on ultrasound...”

# 76816



- An unusual reporting of multiple gestation
  - (Report 76816 with modifier 59 for each additional fetus examined in a multiple pregnancy)
- Fetus 1 76816
- Fetus 2 76816-59
  - Diagnosis O30.0--

# Iris



.....

- Iris is a 35yo G<sub>3</sub>P<sub>1001</sub> @ 32 weeks 2 days with twins, who is being seen by Dr. Irvine for a follow-up growth scan. She has dichorionic/diamniotic twins.

# Iris

# Dr. Irvine



21. DIAGNOSIS OR NATURE OF ILLNESS OR INJURY. Relate A-L to service line below (24E).										22. RESUBMISSION CODE			ORIG REF. NO.		
A.	<b>O30.043</b>			B.	<b>O09.523</b>			C.	<b>Z3A.32</b>			D.			
E.				F.				G.				H.			
										23. PRIOR AUTHORIZATION NUMBER					
I.				J.				K.				L.			
24.A. DATE(S) OF SERVICE From MM DD YY To MM DD YY						B. POS	D. PROCEDURES, SERVICES, OR SUPPLIES (Explain Unusual Circumstances) CPT MODIFIER				E. DX POINTER	F. \$ CHARGES	G. DAYS/ UNITS	I. ID QUAL	J. RENDERING PROVIDER N°
							<b>11</b>	<b>76816</b>			<b>ABC</b>			<b>1</b>	NPI
							<b>11</b>	<b>76816</b>	<b>59</b>		<b>ABC</b>				NPI

## ICD-10 Codes

## ICD-10 Description

**O30.043**

**Twin pregnancy, dichorionic/diamniotic, 3<sup>rd</sup> trimester**

**O09.523**

**Supervision elderly multigravida, 3<sup>rd</sup> trimester**

**Z3A.32**

**32 weeks gestation**

# 76816



.....

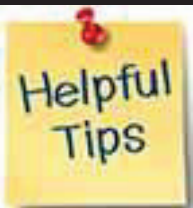- Can you bill 76805 twice in a pregnancy?
- **ACOG Coding Manual states:**
  - “When all the elements of a fetal and maternal evaluation are performed for a subsequent time for a medically necessary reason, the subsequent ultrasound(s) may be reported using this code (76805).”
- But...

# 76817



## Ultrasound, pregnant uterus, real time with image documentation, transvaginal

- “...performed separately or in addition to one of the transabdominal examinations described above.”



# 76817



- May include:
  - Evaluation of the embryo and gestational sac(s)
  - Evaluation of the maternal uterus, adnexa, and/or cervix
- No multiple gestation designation



# 76817



- Universal screening for cervical length
  - Typically done in conjunction with 76805 and/or 76811
  - Gestational age typically somewhere between 18-24 weeks
  - Diagnosis: **Z36.86 Antenatal screening for cervical length**
    - Or, known or suspected cervical problem
  - Reimbursement issues...



# 76817



- Documentation in the Ultrasound Report must clearly state the modality and indication.

***“Transvaginal ultrasound was performed in conjunction with a transabdominal ultrasound to better visualize the cervix. Cervical length appears to be within normal limits for gestational age.***

***Cervical Measurement \_\_\_\_mm”.***

# Janice



- Janice is a 17yo G<sub>2</sub>P<sub>0101</sub> @ 18 weeks 0 days with a previous spontaneous preterm birth, who is presenting to Dr. Jordan for cervical length measurement. There was evidence of cervical shortening.

# Janice

# Dr. Jordan



21. DIAGNOSIS OR NATURE OF ILLNESS OR INJURY. Relate A-L to service line below (24E).										22. RESUBMISSION CODE			ORIG REF. NO.			
A.	<b>O26.872</b>			B.	<b>O09.212</b>			C.	<b>Z3A.18</b>			D.				
E.				F.				G.				H.				
										23. PRIOR AUTHORIZATION NUMBER						
I.				J.				K.				L.				
24.A. DATE(S) OF SERVICE From MM DD YY To MM DD YY						B. POS	D. PROCEDURES, SERVICES, OR SUPPLIES (Explain Unusual Circumstances) CPT MODIFIER				E. DX POINTER	F. \$ CHARGES	G. DAYS/ UNITS	I. ID QUAL	J. RENDERING PROVIDER N°	
							<b>11</b>	<b>76817</b>				<b>ABC</b>		<b>1</b>	NPI	
														NPI		

## ICD-10 Codes

## ICD-10 Description

**O26.872**

**Cervical shortening, 2<sup>nd</sup> trimester**


**O09.212**

**Supervision of pregnancy with history of preterm labor, 2<sup>nd</sup> trimester**

**Z3A.18**

**18 weeks gestation**

# Karen



- Karen, a 26 year old  $G_1P_0$  was sent by her obstetrician to Dr. Kaplan for a 2<sup>nd</sup> trimester anatomy scan and cervical length screening. All findings were within normal limits

# Karen

# Dr. Kaplan



21. DIAGNOSIS OR NATURE OF ILLNESS OR INJURY. Relate A-L to service line below (24E).										22. RESUBMISSION CODE			ORIG REF. NO.			
A.	<b>Z36.3</b>			B.	<b>Z36.86</b>			C.	<b>Z3A.18</b>			D.				
E.				F.				G.				H.				
										23. PRIOR AUTHORIZATION NUMBER						
I.				J.				K.				L.				
24.A. DATE(S) OF SERVICE From MM DD YY To MM DD YY						B. POS	D. PROCEDURES, SERVICES, OR SUPPLIES (Explain Unusual Circumstances) CPT MODIFIER				E. DX POINTER	F. \$ CHARGES	G. DAYS/ UNITS	I. ID QUAL	J. RENDERING PROVIDER N°	
							<b>11</b>	<b>76805</b>				<b>AC</b>			<b>1</b>	NPI
							<b>11</b>	<b>76817</b>				<b>BC</b>				NPI

## ICD-10 Codes

## ICD-10 Description

**Z36.3**

**Encounter for antenatal screening for malformations**

**Z36.86**

**Encounter for antenatal screening for cervical length**

**Z3A.18**

**18 weeks gestation**

# Evaluating service values



Code	Description	Work RVUs	Total RVUs
76801	1 <sup>st</sup> Trimester transabdominal	0.99	3.52
76801-26	1 <sup>st</sup> Trimester transabdominal, Prof. Comp. (PC)	0.99	1.42
76802	1 <sup>st</sup> Trimester transabdominal, ea addl	0.83	1.85
76802-26	1 <sup>st</sup> Trimester transabdominal, ea addl PC	0.83	1.21
76805	2 <sup>nd</sup> /3 <sup>rd</sup> Tri. transabdominal	0.99	4.06
76805-26	2 <sup>nd</sup> /3 <sup>rd</sup> Tri. transabdominal PC	0.99	1.44
76810	2 <sup>nd</sup> /3 <sup>rd</sup> Tri. transabdominal, ea addl	0.98	2.66
76810-26	2 <sup>nd</sup> /3 <sup>rd</sup> Tri. transabdominal, ea addl, PC	0.98	1.43
76811	Detailed ultrasound, 2 <sup>nd</sup> /3 <sup>rd</sup> trimester	1.90	5.22
76811-26	Detailed ultrasound, 2 <sup>nd</sup> /3 <sup>rd</sup> trimester, PC	1.90	2.79
76812	Detailed ultrasound, 2 <sup>nd</sup> /3 <sup>rd</sup> trimester, ea addl	1.78	5.83
76812-26	Detailed ultrasound, 2 <sup>nd</sup> /3 <sup>rd</sup> trimester, ea addl, PC	1.78	2.79

# Evaluating service values



Code	Description	Work RVUs	Total RVUs
76813	Nuchal translucency	1.18	3.48
76813-26	Nuchal translucency, professional component (PC)	1.18	1.75
76814	Nuchal translucency, ea addl	0.99	2.62
76814-26	Nuchal translucency, each addl, PC	0.99	1.47
76815	Limited ultrasound	0.65	2.41
76815-26	Limited ultrasound, PC	0.65	0.93
76816	Follow up ultrasound	0.85	3.30
76816-26	Follow up ultrasound, PC	0.85	1.25
76817	Transvaginal ultrasound	0.75	2.77
76817-26	Transvaginal ultrasound, PC	0.75	1.08



# Biophysical Profile (BPP)



.....


## **76818 (Complete)**

- NST
- Fetal breathing movements
- Fetal movement
- Fetal tone
- Amniotic fluid volume

## **76819 (Incomplete)**

- Fetal breathing movements
- Fetal movement
- Fetal tone
- Amniotic fluid volume

# BPP Scoring



.....


## 76818 (Complete)

- NST = 2
- Fetal breathing movements = 2
- Fetal movement = 2
- Fetal tone = 2
- Amniotic fluid vol. = 2
- **Total 10/10**

## 76819 (Incomplete)

- Fetal breathing movements = 2
- Fetal movement = 2
- Fetal tone = 2
- Amniotic fluid vol. = 2
- **Total 8/8**

# 76818/76819



- An unusual reporting of multiple gestation
  - (Report 76818 with modifier 59 for each additional fetus examined in a multiple pregnancy)
- Fetus 1 76818
- Fetus 2 76818-59
  - Diagnosis: Appropriate for indication

# Other Services with BPP



- Complete BPP (76818) and NST (59025) at ***Same Session***
  - Report only 76818
- Incomplete BPP (76819) and NST (59025) at ***Separate Sessions on same day***
  - Report 76818

# Other Services with BPP



- Complete BPP (76818) and additional NST (59025) during ***Separate Sessions on same day***
  - Report 76818 AND 59025-59
  - Need for 2<sup>nd</sup> NST demonstrated
  - Modifier 59 (Distinct procedure)



# Other Services with BPP

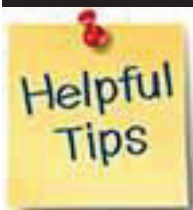

- Complete BPP (76818) and Ultrasounds on ***Same Day***
  - Both BPP and ultrasound reported
  - Ultrasound: ***Anatomic*** examination
  - BPP: ***Physiologic*** examination
- Medical necessity must be supported

# Fetal non-stress test (59025)



- Proper documentation...
  - It is not enough to state “NST reactive” in the progress note to meet the requirements for this service.
  - Prolonged monitoring (or any portion thereof) is not an NST.
    - It’s part of the E/M service for that date.
  - The medical necessity needs to be reflected in both the note and the diagnosis(es).



# Fetal non-stress test (59025)



- Complete BPP (76818) and Ultrasounds on ***Same Day***
  - Both BPP and ultrasound reported
  - Ultrasound: ***Anatomic*** examination
  - BPP: ***Physiologic*** examination
- Medical necessity must be supported





# Reporting 59025



- Two in one day
  - 59025 and 59025-76/59025-77
- Twins
  - 59025 x 2 or
  - 59025 and 59025-59
- Most payers won't reimburse more than 2 per day per fetus
  - But only if clinical indications are present

# Lisa



- Lisa is a 25yo G<sub>1</sub>P<sub>0</sub> @ 34 weeks 3 days with GDMA, managed with insulin and fetal growth restriction at the 7<sup>th</sup> percentile (AC<3<sup>rd</sup>). Today, she presents to Dr. Lewis for a fetal growth ultrasound and antenatal testing (biophysical profile with NST)

Lisa

Dr. Lewis



21. DIAGNOSIS OR NATURE OF ILLNESS OR INJURY. Relate A-L to service line below (24E).										22. RESUBMISSION CODE			ORIG REF. NO.			
A.	<b>O24.410</b>			B.	<b>O36.5930</b>			C.	<b>Z3A.34</b>			D.				
E.				F.				G.				H.				
23. PRIOR AUTHORIZATION NUMBER																
I.				J.				K.				L.				
24.A. DATE(S) OF SERVICE From MM DD YY To MM DD YY						B. POS	D. PROCEDURES, SERVICES, OR SUPPLIES (Explain Unusual Circumstances) CPT MODIFIER				E. DX POINTER	F. \$ CHARGES	G. DAYS/ UNITS	I. ID QUAL	J. RENDERING PROVIDER N°	
							<b>11</b>	<b>76816</b>				<b>ABC</b>		<b>1</b>	NPI	
							<b>11</b>	<b>76818</b>				<b>ABC</b>		<b>1</b>	NPI	

### ICD-10 Codes

### ICD-10 Description

**O24.410**

**Gestational diabetes mellitus in pregnancy, 3<sup>rd</sup> trimester**


**O36.5930**

**Maternal care for other known or suspected poor fetal growth**

**Z3A.34**

**34 weeks gestation**

# Other antenatal testing



- **76820**

**Doppler velocimetry, fetal; umbilical artery**

# 76820



- Measuring velocity of blood flow through umbilical artery
  - To identify abnormalities present in a growth-retarded fetus
  - Same code for “initial” or “subsequent” study
  - Performed transabdominally or transvaginally
  - Use 59 modifier on multiple fetuses
  - Includes color flow mapping (93325)

# 76821



## **Doppler velocimetry, fetal; middle cerebral artery**

- Measuring velocity of blood flow through middle cerebral artery
  - Peak velocity is inversely related to the fetal hematocrit
    - Fetal cardiovascular distress
    - Fetal anemia
    - Fetal hypoxia


# 76821



## **Doppler velocimetry, fetal; middle cerebral artery**

- Transabdominal or transvaginal
- Use 59 modifier on multiple fetuses
- Includes color flow mapping (93325)

# Mary



- Mary is a 35yo G<sub>3</sub>P<sub>1001</sub> @ 35 weeks 2 days with congenital pulmonary airway malformation (CPAM), fetal growth restriction, AMA, and a history of prior cesarean delivery (x2). Today, she presents to Dr. Morton at her hospital-based practice for a follow-up growth ultrasound growth ultrasound, BPP, and Doppler surveillance.



# Mary

# Dr. Morton



21. DIAGNOSIS OR NATURE OF ILLNESS OR INJURY. Relate A-L to service line below (24E).										22. RESUBMISSION CODE		ORIG REF. NO.									
A.	<b>O09.893</b>			B.	<b>O35.8XX0</b>			C.	<b>O36.5930</b>			D.	<b>O09.523</b>								
E.	<b>O34.219</b>			F.	<b>Z3A.35</b>			G.				H.				23. PRIOR AUTHORIZATION NUMBER					
I.				J.				K.				L.									
24.A. DATE(S) OF SERVICE From MM DD YY To MM DD YY						B. POS		D. PROCEDURES, SERVICES, OR SUPPLIES (Explain Unusual Circumstances) CPT MODIFIER				E. DX POINTER		F. \$ CHARGES		G. DAYS/ UNITS		I. ID QUAL		J. RENDERING PROVIDER N°	
							<b>22</b>	<b>76816</b>	<b>26</b>		<b>ADEF</b>			<b>1</b>		NPI					
							<b>22</b>	<b>76820</b>	<b>26</b>		<b>ABCF</b>			<b>1</b>		NPI					
							<b>22</b>	<b>76821</b>	<b>26</b>		<b>ABCF</b>			<b>1</b>		NPI					

## ICD-10 Codes

## ICD-10 Description

<b>O09.893</b>	<b>Supervision of high risk pregnancy in third trimester</b>
<b>O35.8XX0</b>	<b>Maternal care for other (suspected) fetal abnormality &amp; damage</b>
<b>O36.5930</b>	<b>Pregnancy affected by fetal growth restriction</b>
<b>O09.523</b>	<b>Elderly multigravida in third trimester</b>
<b>O34.219</b>	<b>History of cesarean delivery</b>
<b>Z3A.35</b>	<b>35 weeks gestation of pregnancy</b>

# Fetal Echocardiography



- **76825** Echocardiography, fetal, cardiovascular system, real time with image documentation (2D), with or without M-mode recording;
- **76826** follow-up or repeat study

# Fetal Echocardiography



- **76827**      **Doppler echocardiography, fetal, pulsed wave and/or continuous wave with spectral display; complete**
- **76828**      **follow-up or repeat study**


# 76825



.....  
Ultrasonic procedure to identify congenital anomalies, such as:


- Atrial and ventricular septal defects
- Aortic stenosis
- Hypoplastic left heart syndrome
- Cardiomyopathy
- Assessment of functional abnormalities

# 76825 service includes



- Evaluation of all parts of the fetal heart, including venous connections, chambers, competence/movement of valves and great arterial connections
  - Four-chambered view
  - Left ventricular outflow tract
  - Right ventricular outflow tract
  - Three-vessel and trachea view

# 76825 service includes



- Evaluation of all parts of the fetal heart, including venous connections, chambers, competence/movement of valves and great arterial connections
  - Short axis views (“low” for ventricles and “high” for outflow tracts)
  - Aortic arch
  - Ductal arch
  - Superior vena cava (SVC)
  - Inferior vena cava (IVC)

# Maternal indications for 76825



- Autoimmune antibodies, anti-Ro (SSA)/anti-La (SSB)
- Familial inherited disorders (e.g., Marfan syndrome)
- First-degree relative with congenital heart disease
- In vitro fertilization
- Metabolic disease (e.g., diabetes mellitus and phenylketonuria)
- Teratogen exposure (e.g., retinoids and lithium)



# Fetal indications for 76825



- Abnormal cardiac screening examination
- Abnormal heart rate or rhythm
- Fetal chromosomal anomaly
- Extracardiac anomaly
- Hydrops
- Increased nuchal translucency
- Monochorionic twins



# 76826 service includes



## ***Follow-up or repeat study***


- Assessment of cardiac function
- Evaluation of the heart anomaly (e.g. frequency of runs of supraventricular tachycardia in the fetus)
- Typically identified in and pertinent to an initial examination.

# Fetal Doppler Echocardiography CPT 76827



- Reported with 76825 when the clinical indications exist. Spectral, continuous wave, color, and/or power Doppler sonography can be used to evaluate the following structures for potential flow or rhythm disturbances.
- Fetal Doppler Echocardiography evaluates the velocity and turbulence of blood flow within the fetal cardiovascular system.

# 76827



The service includes:

- Atrioventricular valves
- Semilunar valves
- Ductus Venosus
- Umbilical vein and artery (optional)
- Cardiac rhythm disturbance, and
- Any structure in which an abnormality is noted.


# Fetal indications for 76827



Fetal Indications, including but not limited to:

- Anatomical/structural
- Functional/dysrhythmia


# 76828 service includes:



## ***Follow-up or repeat study***

- This code is used to report follow-up or repeat fetal Doppler echocardiography.


+93325



**Doppler echocardiography color flow velocity mapping (List separately in addition to codes for echocardiography)**

(Use 93325 in conjunction with **76825, 76826, 76827, 76828**, 93303, 93304...)

# Color flow mapping (93325)



Echocardiography includes obtaining ultrasonic signals from the heart and great arteries, with two-dimensional image and/or Doppler ultrasonic signals documentation, interpretation and report.

93325



AIUM Guidelines state:

*“Color Doppler Sonography should be used to evaluate the following structures for potential flow disturbances”:*



# 93325



- Systemic veins (including superior and inferior vena cava and Ductus Venosus)
- Pulmonary veins
- Foramen ovale
- Atrioventricular valves
- Atrial and ventricular septa
- Semilunar valves
- Ductal arch
- Aortic arch
- Umbilical vein and artery (optional).


# Documenting 93325



- How do you document 93325?

***“Color flow mapping was utilized during this fetal cardiac study.”***

# Nancy



- Nancy is a 35yo G<sub>2</sub>P<sub>1001</sub> @ 24 weeks 5 days with history of prior offspring with right sided-aortic arch. Her prior pregnancy was notable for gestational diabetes, but was otherwise uncomplicated with delivery at term. Today, she presents to Dr. Norton for a screening fetal echocardiogram with color Doppler flow mapping and follow-up fetal growth ultrasound.

Nancy  
Norton

Dr.



21. DIAGNOSIS OR NATURE OF ILLNESS OR INJURY. Relate A-L to service line below (24E).										22. RESUBMISSION CODE		ORIG REF. NO.				
A.	<b>O09.292</b>			B.	<b>O09.522</b>			C.	<b>Z86.32</b>			D.	<b>Z3A.24</b>			
E.				F.				G.				H.				
23. PRIOR AUTHORIZATION NUMBER																
I.				J.				K.				L.				
24.A. DATE(S) OF SERVICE From MM DD YY To MM DD YY						B.	D. PROCEDURES, SERVICES, OR SUPPLIES (Explain Unusual Circumstances) CPT MODIFIER				E.	F.		G.	I.	J.
						POS					DX POINTER	\$ CHARGES		DAYS/ UNITS	ID QUAL	RENDERING PROVIDER N°
						11	76816				ABCD			1	NPI	
						11	76825				ABCD			1	NPI	
						11	76827				ABCD			1	NPI	
						11	93325				ABCD			1	NPI	

### ICD-10 Codes

### ICD-10 Description

**O26.292**

**Supervision of pregnancy with other poor reproductive or obstetric history, 2nd trimester**

**O09.522**

**Advanced maternal age, multigravida, 2<sup>nd</sup> trimester**

**Z86.32**

**Personal history of gestational diabetes**

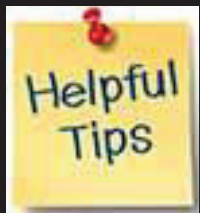**Z3A.24**


**24 weeks gestation**

# Ductus Venosus Doppler



- There is **not** a specific CPT Code for reporting a Ductus Venosus Doppler. If it is sampled **as part of a new or repeat fetal Doppler echocardiogram**, for standard indications, the following codes would be correct.





# How to bill other services...



- Ductus venosus Doppler
  - Billable as part of 76827/76828
  - Not separately billable alone
- Ductus arteriosus Doppler
  - Billable as part of 76827/76828
  - Not separately billable alone
- PR interval measurement
  - Typically 76828

# Reporting 3D ultrasound



- 76376** 3D rendering with interpretation and reporting of computed tomography, magnetic resonance imaging **ultrasound**, or other tomographic modality; **not requiring** image post processing on an independent workstation.
- 76377** requiring image post processing on an independent workstation



# Questions **about ultrasound?**